

Age and Sex-Related Variation in Hyoid Bone Morphology

REFERENCE: Miller KWP, Walker PL, O'Halloran RL. Age and sex-related variation in hyoid bone morphology. *J Forensic Sci* 1998;43(6):1138–1143.

ABSTRACT: Although the relationship between hyoid bone shape and fracture pattern figures prominently in forensic investigations of strangulation, few quantitative data exist on age and sex differences in hyoid morphology. An image analysis system was used to take a series of 30 measurements on digitized radiographs of 315 hyoid bones from people of known age and sex. The degree of fusion of the greater cornua to the hyoid body was also recorded. Statistical analysis of these data shows that there is a continuous distribution of hyoid bone shapes and that most bones are highly symmetrical. Based on smaller samples, previous researchers have suggested that non-fusion is more common in women than in men. In contrast, our data suggest that men and women have similar non-fusion rates. Analysis of sexual dimorphism shows that the greatest length differences are in the greater cornua. There are also significant sex differences in hyoid shape. For example, the distal ends of the greater cornua of women are significantly longer than those of men.

KEYWORDS: hyoid bone, strangulation, asphyxiation, sexual dimorphism, age determination, skeletal biology, osteology, forensic anthropology, homicide

The hyoid bone is of considerable forensic interest owing to its susceptibility to fracture during manual strangulation. For example, the presence of a fractured hyoid bone is often of great importance in cases involving badly decomposed bodies and skeletal remains lacking soft tissue evidence of neck injury. A hyoid bone's shape may influence its susceptibility to fracture (1–6) and hyoid fractures are frequently confused with normal variation in both clinical (7) and forensic settings (8,9). In spite of the importance of understanding normal age and sex variation in these contexts, few systematic studies of hyoid bone morphology have been conducted. To remedy this situation, we have analyzed age and sex variation in the morphology of a large sample of hyoid bones taken at autopsy.

Materials and Methods

Hyoid bones were examined from 188 males and 127 females during autopsies conducted between 1986 and 1997 at the Ventura County (California) Medical Examiner's Office. Although age at death ranged from two months to 93 years (Table 1), only 7 individuals were younger than 15 years old. As is typical of autopsy samples, the average age of the males (41.7 years) is significantly ($t = 3.9$; $p < t = 0.0001$) younger than that of the females (50.3

years). Data on height, weight, and ethnicity were also collected. Whites and Hispanics made up 96% of the sample.

In each case, the hyoid was carefully dissected from the larynx and surrounding connective tissues. Care was taken to retain enough connective tissue so that the bone's overall shape was preserved. Each specimen was radiographed with its inferior surface resting directly on the cassette, 50 in. (127 cm) from the X-ray source with an exposure of 50 kVp and 1.25 mAs. A radiopaque scale was included in all radiographs, but tests showed that magnification effects were negligible.

The radiographs were converted into digital images using a high resolution (600 dpi) scanner and measured using the Sigma Scan image analysis program. After size calibration, multiple measurements were made on each bone (Fig. 1, Table 2). In addition to making these measurements, the degree of fusion of the greater cornua to the hyoid body was recorded.

Results

Shape

Although the hyoid bone can generally be described as being "U-shaped" (10), "hyperbolic" (dimensions of breadth and length are similar) and "parabolic" (dimensions of breadth are greater than length) variants have been described (11). These shape differences have been related to fracture patterns in the forensic literature (4,6). Our data show that hyoid width/length ratios are continuously distributed and do not fall into discrete categories. Tests of skewness and kurtosis (12) indicate that the distribution of hyoid width/length ratios does not deviate significantly from a normal distribution (skewness: $p = 0.62$, kurtosis: $p = 0.19$). These data suggest that dividing hyoid bones into "hyperbolic" and "parabolic" types is to some extent arbitrary (Fig. 2).

Age and sex differences in hyoid asymmetry were investigated through analysis of covariance. An analysis of absolute differences between bilateral length measurements, controlling for age, does not reveal significant sex differences in asymmetry. Asymmetry in bone length is greater than asymmetry in bone width, and this increases significantly with advancing age. However, the degree of fusion also increased with advancing age making the line delineating the cornua from the body less well defined. Measurement error may, therefore, have contributed to the age-related increase we found in length asymmetry.

Fusion of the Body and Greater Cornua

Our data show that there is considerable age variation in fusion of the greater cornua to the hyoid body (Fig. 3). Although the proportion of people with bilateral fusion steadily increases with increasing age, many elderly individuals have either unilateral or bilateral non-fusion (Table 3).

¹ Department of Anthropology, University of California at Santa Barbara, Santa Barbara, CA.

² Ventura County Medical Examiner, Ventura, CA.

Received 26 Jan. 1998; and in revised form 18 March 1998; accepted 20 March 1998.

In contrast to previous studies based on smaller samples, we found little evidence for a sex difference in the age at which bilateral fusion occurs. No significant differences were found between men and women in the proportion of individuals with bilateral fusion when the sample was divided at ten-year intervals by age at death. The >40–50 age group (Fig. 3) is the only one that approached statistical significance in this regard ($\chi^2 = 4.0$, $p = 0.046$). A much larger proportion of females in this age group showed bilateral non-fusion than did the females who died in the preceding decade of life (50% vs. 37%). Since there is no reason to believe that age-specific mortality related to non-fusion would differentially affect women in their forties, it seems likely that the apparent increase in non-fusion among women in this age group is the result of sampling error.

In contrast to previous studies with smaller sample sizes, our data show that bilateral non-fusion persists in a significant proportion of the elderly population. Bilateral non-fusion was present in nearly 30% of the people in our sample who were 70 years of age or older (Table 3). It is worth noting that in people with unfused greater cornua, there is a gradual decrease in the size of the articular space until the age of 40 ($r = 0.67$, $p = 0.00001$). In contrast, there is no clear relationship between joint space width and increasing age in people older than 40 ($r = -0.21$, $p = 0.13$). Although interpreting this is difficult owing to the cross-sectional nature of our data, it suggests that fusion is not a continuous process. People may instead have a genetic predisposition to fusion or non-fusion.

Sexual Dimorphism

Although most hyoid bone dimensions are significantly larger in men than in women, some measurements are much more sexually dimorphic than others (Table 4). In general, lengths are more sexually dimorphic than widths (Table 5). When we used analysis of covariance to control for the effects of age at death and fusion, we found statistically significant sex differences in 79% ($n = 19$)

of the length measurements. Such differences were present in only 40% ($n = 10$) of the width measurements.

Discussion

Shape

Although hyoid bones can be classified into “hyperbolic” and “parabolic” types (6,11), our data suggest that the pattern of hyoid shape variation is continuous rather than bimodal. Thus, in addition to being inherently subjective, using such a dichotomous system results in loss of morphological information.

The hyoid bone shows a complicated pattern of sexual dimorphism. Consistent with earlier reports (1), the most striking differences we found between men and women were in total bone length and total bone width. The lengths of the greater cornua are obviously the primary contributors to total bone length. Interestingly, however, only a few segmental measurements of width and length of the greater cornua account for the sex differences observed in this bone as a whole.

There is an apparent contradiction in the fact that although greater cornu length seems to increase susceptibility to fracture (5), the relatively small hyoids of women fracture more frequently during strangulation than do those of men (5,13,14). This sex difference might possibly be explained by behavioral differences in the assailants of men and women. Alternatively, peculiarities in the shape of the female hyoid may increase its susceptibility to fracture. Our observation that female hyoids have relatively long, thin distal segments (see measurements 19 and 29) may possibly be significant in this regard. This is consistent with the observation that hyoid fractures frequently occur in the posterior and middle thirds and rarely in the anterior portions of the greater cornua (11). However, additional observations of hyoid fractures are needed to confirm the hypothesis that the shape of the female hyoid increases its fracture susceptibility.

We were not as successful as some previous investigators (3) in developing a discriminant function that uses hyoid measurements for sex determination. With an equation derived using the stepwise technique we were able to correctly classify 69.2% of the males and 75.2% of the females in our sample. This equation incorporated the following measurements: 2, 4, 17, 20, and 29. This list provides the maximum discrimination between males and females and confirms our conclusion, based on the analysis of individual measurements, that the distal ends of the greater cornua are more highly sexually dimorphic than other parts of the bone. Specifically, the distal ends of the greater cornua (lengths 18 and 19 on the left side and 29 and 30 on the right) are larger in females than in males. The portion of the bone proximal to this (length 20

TABLE 1—Age and sex distribution of sample used in study.

Age in Years	Males	Females	Total
0–10	2	2	4
11–20	29	6	35
21–30	31	17	48
31–40	36	17	53
41–50	29	22	51
51–60	25	20	45
61–70	21	20	41
71 and above	15	23	38
Total	188	127	315

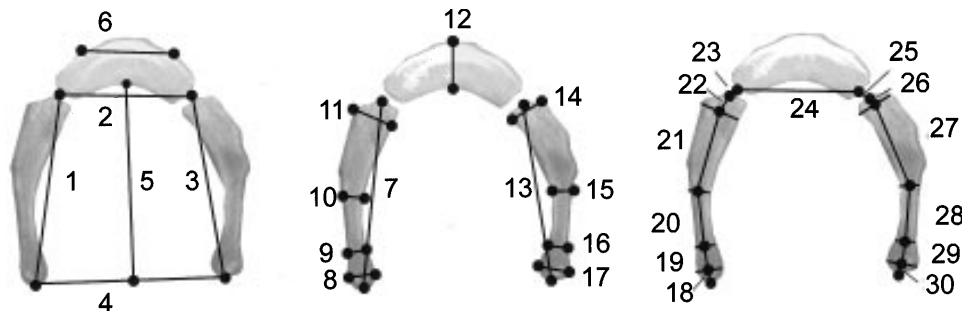


FIG. 1—Illustration showing measurements defined in text.

TABLE 2—*Osteometric measurements taken of each hyoid bone (diagrammed in Fig. 1).*

Measurement	Description
1	Distance from the midpoint of the distal end of the left greater cornu to the middle of the joint between the left greater cornu and the left side of the body of the hyoid.
2	Distance from the middle of the left joint space to the middle of the right joint space measured across the body of the hyoid (in bones exhibiting fusion of one or both cornua to the hyoid body, the points of measurement are taken to be the midpoints of the lines of fusion evident on X-ray).
3	Distance from the midpoint of the distal end of the right greater cornu to the middle of the joint between the right greater cornu and the right side of the body of the hyoid.
4	Distance between the distal ends of the right and left greater cornua, measured from the center of each bone.
5	Perpendicular distance from the midpoint of a line drawn between the distal ends of the right and left greater cornua (measurement 4) to the midpoint of the posterior aspect of the hyoid body.
6	Distance between the points defined by the change in curvature of the anterior surface of the hyoid body associated with the lateral borders of the area for the insertion of the geniohyoid muscle.
7	Maximum length of the left greater cornu.
8	Maximum diameter of the distal end of the left greater cornu, measured perpendicular to the internal surface of the bone.
9	Minimum diameter of the distal end of the left greater cornu, measured perpendicular to the internal surface of the bone.
10	Width of the left greater cornu measured perpendicular to the internal surface of the bone at the midpoint of the maximum length of the greater cornu.
11	Maximum width of the proximal end of the left greater cornu, measured perpendicular to the internal surface of the bone.
12	Width of the hyoid body at its midpoint, measured perpendicular to the surface of the bone.
13	Maximum length of the right greater cornu.
14	Maximum width of the proximal end of the right greater cornu, measured perpendicular to the internal surface of the bone.
15	Width of the right greater cornu measured perpendicular to the internal surface of the bone at the midpoint of the maximum length of the greater cornu.
16	Minimum diameter of the distal end of the right greater cornu, measured perpendicular to the internal surface of the bone.
17	Maximum diameter of the distal end of the right greater cornu, measured perpendicular to the internal surface of the bone.
18	Length of the distance from the distal end of the left greater cornu to the midpoint of the widest segment of the distal end of the left greater cornu (measurement 11), measured through the central axis of the greater cornu.
19	Length of the distance from the midpoint of the widest segment of the distal end of the left greater cornu (measurement 11) to the midpoint of the narrowest segment of the left greater cornu (measurement 10), measured through the central axis of the greater cornu.
20	Length of the distance from the narrowest segment of the left greater cornu (measurement 10) to a point equidistant between the distal and proximal ends of the left greater cornu (measurement 7), measured through the central axis of the greater cornu.
21	Length of the distance from the point equidistant between the distal and proximal ends of the left greater cornu to the widest portion of the proximal end of the left greater cornu measured through the central axis of the greater cornu.
22	Length of the distance from the widest portion of the proximal segment of the left greater cornu (measurement 8) to the midpoint of the proximal end of the left greater cornu, measured through the central axis of the greater cornu.
23	Length of the distance from the midpoint of the proximal end of the left greater cornu to the midpoint of the left side of the hyoid body (not measured in bones where the left greater cornu is fused to the hyoid body).
24	Length of the distance from the midpoint of the left side of the hyoid body to the midpoint of the right side of the hyoid body measured through the central axis of the hyoid body.
25	Length of the distance from the midpoint of the right proximal end of the greater cornu to the midpoint of the right side of the hyoid body (not measured in bones where the right greater cornu is fused to the hyoid body).
26	Length of the distance from the widest portion of the proximal segment of the right greater cornu (measurement 14) to the midpoint of the proximal end of the right greater cornu, measured through the central axis of the greater cornu.
27	Length of the distance from the point equidistant between the distal and proximal ends of the right greater cornu to the widest portion of the proximal end of the right greater cornu measured through the central axis of the greater cornu.
28	Length of the distance from the narrowest segment of the right greater cornu (measurement 16) to a point equidistant between the distal and proximal ends of the left greater cornu (measurement 13), measured through the central axis of the bone.
29	Length of the distance from the midpoint of the widest segment of the distal end of the right greater cornu (measurement 17) to the midpoint of the narrowest segment of the right greater cornua (measurement 16), measured through the central axis of the greater cornu.
30	Length of the distance from the distal end of the right greater cornua to the midpoint of the widest segment of the distal end of the right greater cornu (measurement 17), measured through the central axis of the greater cornu.
31	The total length of the hyoid bone as defined by the sum of measurement 5 and measurement 12.

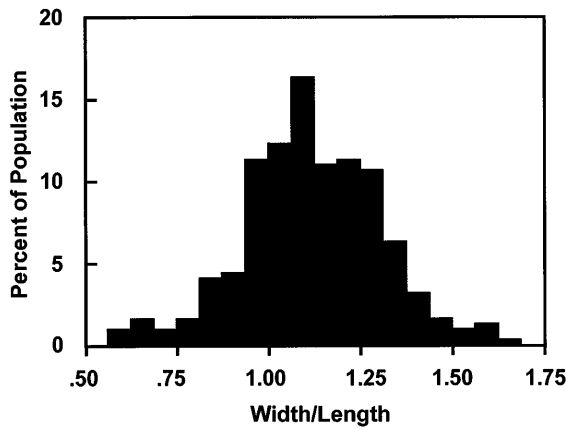


FIG. 2—Frequency distribution of ratio of total width to total length of the hyoid bone (measurement 4/measurement 31).

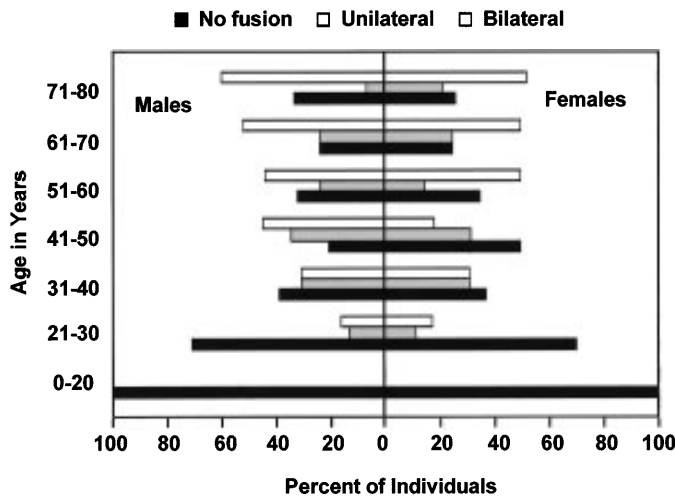


FIG. 3—Age distribution of males and females with bilateral, unilateral, and non-fusion of the greater cornua to the hyoid body.

on the left and 28 on the right), in contrast, is much larger in males than in females.

Although the functional significance of the sex differences in the distal end of the greater cornua is unclear, it is possible that the age differences between the males and females in our sample have somehow contributed to the sexual dimorphism we observed in this area. In early childhood, the distal ends of the greater cornua have a “truncated” appearance. With increasing age, these gradually become more rounded and take on a more “clubbed” appearance. In elderly individuals, the distal ends of the greater cornua again appear to be flattened. This same phenomenon was described by Jelisiejew et al. nearly 30 years ago (1). While the distal ends of the greater cornua cannot be used to predict age accurately, mature adults with truncated distal ends tend to be older individuals.

Fusion

Other researchers have suggested, based on smaller samples, that complete fusion of the greater cornua to the body of the hyoid is rare until the third (15) and even fourth (16) decades of life. Our data contradict this. They show that hyoid fusion is quite common during the third decade with 13% of individuals in this age group having unilateral fusion and 17% having bilateral fusion (Table 3).

Although there is an overall increase in the frequency of fused hyoids with increasing age (15), our data show that the proportion of people with bilateral non-fusion remains relatively constant at about 30% after the fourth decade of life. Our data also do not reveal any marked sex differences in fusion. The proportion of men and women with bilateral non-fusion is roughly equal and remains more or less constant after the fifth decade of life.

Conclusions

Our analysis of age and sex variation in hyoid bone morphology suggests that some of the assumptions of previous investigators need to be reassessed. For example, we find little evidence for sex differences in the age at which the greater cornua fuse to the hyoid body. Our data also suggest that dividing hyoids in to parabolic and hyperbolic types is unwarranted since the underlying shape

TABLE 3—Age and sex differences in the frequency of unilateral and bilateral fusion of the left and right greater cornua to the body of the hyoid.

Age Group		Fusion in Males			Fusion in Females			Fusion in Both Sexes		
		None	1 Side	2 Sides	None	1 Side	2 Sides	None	1 Side	2 Sides
0–10	N	2	0	0	2	0	0	4	0	0
	%	100.0	0.0	0.0	100.0	0.0	0.0	100.0	0.0	0.0
11–20	N	29	0	0	6	0	0	35	0	0
	%	100.0	0.0	0.0	100.0	0.0	0.0	100.0	0.0	0.0
21–30	N	22	4	5	12	2	3	34	6	8
	%	71.0	12.9	16.1	70.6	11.8	17.6	70.8	12.5	16.7
31–40	N	14	11	11	6	5	5	20	16	16
	%	38.9	30.6	30.6	37.5	31.3	31.3	38.5	30.8	30.8
41–50	N	6	10	13	11	7	4	17	17	17
	%	20.7	34.5	44.8	50.0	31.8	18.2	33.3	33.3	33.3
51–60	N	8	6	11	7	3	10	15	9	21
	%	32.0	24.0	44.0	35.0	15.0	50.0	33.3	20.0	46.7
61–70	N	5	5	11	5	5	10	10	10	21
	%	23.8	23.8	52.4	25.0	25.0	50.0	24.4	24.4	51.2
71–80	N	5	1	9	6	5	12	11	6	21
	%	33.3	6.7	60.0	26.1	21.7	52.2	28.9	15.8	55.3
Total	N	91	37	60	55	27	44	146	64	104
	%	48.4	19.7	31.9	43.7	21.4	34.9	46.5	20.4	33.1

TABLE 4—Mean measurements in millimeters (\pm S.D.) for males ($n = 182$) and females ($n = 125$) greater than 15 years old.

Variable	Minimum Distance		Maximum Distance		Mean Dist. (\pm S.D.)		M/F \times 100
	Male	Female	Male	Female	Male	Female	
1	18.2	17.1	40.7	37.6	28.6 \pm 5.1	27.7 \pm 4.3	103.1
2	13.8	12.9	28.9	26.0	21.4 \pm 3.4	19.8 \pm 3.0	108.1
3	16.9	18.1	40.3	37.3	28.5 \pm 5.2	27.3 \pm 4.4	104.4
4	18.5	18.8	67.1	59.9	39.8 \pm 9.3	40.1 \pm 8.1	99.3
5	16.3	15.4	38.1	34.8	27.3 \pm 5.1	25.3 \pm 4.2	108.0
6	9.6	8.7	27.9	27.9	17.6 \pm 4.5	17.0 \pm 4.1	103.6
7	17.5	17.3	41.0	37.2	28.3 \pm 5.2	27.5 \pm 4.2	103.0
8	1.6	1.9	6.1	6.2	3.3 \pm 1.0	3.5 \pm 0.8	94.9
9	1.0	0.9	3.6	3.8	2.1 \pm 0.6	2.1 \pm 0.6	100.2
10	1.4	1.2	5.8	5.4	3.0 \pm 0.9	3.0 \pm 0.8	102.6
11	2.9	2.5	8.8	6.9	5.0 \pm 1.2	4.7 \pm 0.9	107.0
12	4.3	2.6	12.6	12.1	7.9 \pm 1.8	7.4 \pm 1.6	106.6
13	18.0	17.4	40.1	37.9	28.3 \pm 5.2	27.3 \pm 4.5	103.6
14	2.3	1.7	8.5	7.6	5.1 \pm 1.1	4.7 \pm 1.0	107.5
15	1.1	1.3	5.2	5.1	2.9 \pm 0.8	2.8 \pm 0.8	102.0
16	0.7	1.0	3.4	4.1	2.0 \pm 0.5	2.1 \pm 0.6	96.5
17	1.5	1.9	5.6	6.1	3.3 \pm 0.9	3.5 \pm 0.8	92.8
18	0.0	0.1	5.0	6.6	1.8 \pm 0.7	1.9 \pm 0.9	98.2
19	0.7	1.4	10.2	11.7	3.8 \pm 2.0	4.5 \pm 2.2	83.9
20	4.6	1.4	14.0	13.6	8.7 \pm 1.9	7.6 \pm 2.2	114.8
21	4.9	5.8	18.5	17.3	11.3 \pm 2.9	11.2 \pm 2.3	100.6
22	4.9	5.8	18.5	17.3	11.3 \pm 2.9	11.2 \pm 2.3	100.6
23	0.9	0.0	8.3	5.8	3.3 \pm 1.1	2.8 \pm 1.0	116.9
24	0.0	0.0	4.3	3.1	0.7 \pm 0.9	0.6 \pm 0.7	119.1
25	12.7	11.3	29.2	25.6	20.9 \pm 3.5	19.4 \pm 3.0	107.7
26	0.0	0.0	4.3	3.4	0.8 \pm 0.8	0.6 \pm 0.7	128.8
27	0.8	0.9	8.0	5.9	3.1 \pm 1.1	2.7 \pm 1.0	115.8
28	5.3	5.9	19.0	16.9	11.4 \pm 2.8	11.2 \pm 2.5	102.1
29	0.9	2.4	15.7	13.9	8.3 \pm 2.1	7.2 \pm 2.0	115.8
30	1.1	1.3	13.5	11.9	4.2 \pm 2.5	4.9 \pm 2.3	84.8
31	23.6	21.3	48.3	44.2	35.2 \pm 5.8	32.7 \pm 4.7	107.7

TABLE 5—Analysis of covariance of hyoid dimensions controlling for sex, age at death, and fusion of the hyoid body to the greater cornua.

Measurement		Sex		Age		Fusion	
		F	P	F	P	F	P
Lengths	1	4.48	0.04*	10.05	<0.01*	0.34	0.71
	2	24.56	0.00*	13.16	<0.01*	1.85	0.16
	3	7.03	0.01*	11.48	<0.01*	0.47	0.63
	5	15.80	0.00*	7.05	0.01*	0.15	0.86
	6	2.48	0.12	5.41	0.02*	0.70	0.50
	7	4.62	0.03*	13.25	<0.01*	0.92	0.40
	13	5.58	0.02*	14.13	<0.01*	0.45	0.64
	18	1.05	0.31	36.04	<0.01*	1.43	0.24
	19	6.63	0.01*	2.87	0.09	0.36	0.70
	20	20.24	0.00*	0.49	0.49	1.35	0.26
	21	0.56	0.45	5.92	0.02*	0.43	0.65
	22	14.93	0.00*	3.87	0.05*	0.78	0.46
	24	24.34	0.00*	24.11	0.00*	4.67	0.01*
	26	13.65	0.00*	5.56	0.02*	1.59	0.21
27	1.56	0.21	6.37	0.01*	0.81	0.45	
28	19.44	0.00*	1.33	0.25	0.04	0.96	
29	5.57	0.02*	0.80	0.37	0.14	0.87	
30	3.73	0.05*	29.60	<0.01*	2.77	0.06	
31	18.57	0.00*	8.60	<0.01*	0.31	0.74	
Widths	4	0.71	0.40	20.03	0.00*	4.05	0.02*
	8	1.11	0.29	3.51	0.06	0.66	0.52
	9	0.46	0.50	5.97	0.02*	0.21	0.81
	10	0.54	0.46	0.00	0.98	0.37	0.69
	11	7.87	0.01*	3.11	0.08	1.72	0.18
	12	7.08	0.01*	3.87	0.05*	0.83	0.44
	14	11.55	0.00*	5.91	0.02*	5.84	0.00*
	15	0.40	0.53	0.02	0.90	0.11	0.90
	16	1.18	0.28	0.03	0.86	0.96	0.38
17	4.55	0.03*	2.23	0.14	0.52	0.59	

distribution is continuous. Our analysis of sexual dimorphism in hyoid shape revealed subtle sex differences in the distal ends of the greater cornua that may be correlated with fracture patterns.

Much has been learned about hyoid bone variability in recent years, but more information is still needed. For example, additional data on the individuals under-represented in this study—namely women 31 to 40 years old and individuals of both sexes under 15 years of age—would be particularly helpful. Also, very little is known about the age and sex variation of the lesser cornua. Although these small, highly variable structures are difficult to see in radiographs, they are a potential source of additional information for use in forensic investigations.

Acknowledgments

The authors would like to thank the members of the Ventura County Medical Examiner's Office for assistance with sample collection, members of the radiology staff at the Ventura County Medical Center for radiograph development, and S. Breitwieser for assistance with Sigma Plot measurements.

References

1. Jelisiejew T, Szmurlo J, Kuduk I. Morphologic studies on the hyoid bone in man. *Folia Morphologica* 1968;27:172–82.
2. Iserson K. Strangulation: A review of ligature, manual, and postural neck compression injuries. *Ann Emergency Med* 1984;13:179–85.
3. Guilbeau MG. Forensic application of the skeletonized hyoid bone and ossified structures of the larynx in an adult American sample. Ph.D. thesis, University of Tennessee, 1992.
4. Ubelaker, DH. Hyoid fracture and strangulation. *J Forensic Sci* 1992;37:1216–22.

5. Pollanen MS, Chiasson DA. Fracture of the hyoid bone in strangulation: Comparison of fractured and unfractured hyoids from victims of strangulation. *J Forensic Sci* 1996;41:110–3.
6. Pollanen MS, Ubelaker DH. Forensic significance of the polymorphism of hyoid bone shape. *J Forensic Sci* 1997;42:890–2.
7. Szeremeta W, Morovati SS. Isolated hyoid bone fracture: A case report and review of the literature. *J Trauma* 1991;31:268–71.
8. Gordon I, Shapiro HA, Taljaard JJF, Engelbrecht HE. Aspects of the hyoid-larynx complex in forensic pathology. *J Forensic Sci* 1976;7:161–70.
9. Rodriguez WC. Morphological variation and fracture patterns in the hyoid bone. *Abstr Am Acad Forensic Sci*, 1986. Annual Meeting February 10–15: #H7.
10. Williams PL, Warwick R, Dyson M, Bannister LH, editors. *Gray's anatomy*. 37th ed. London: Churchill Livingstone, 1989.
11. Pollanen MS, Bulger B, Chiasson DA. The location of hyoid fractures in strangulation revealed by xeroradiography. *J Forensic Sci* 1995;40:303–5.
12. Di Agostino RB, Balanger A, DiAgostino RBJ. A suggestion for using powerful and informative tests of normality. *American Statistician* 1990;44:316–21.
13. Line WS, Stanley RB, Choi JH. Strangulation: a full spectrum of blunt neck trauma. *Ann Otol Rhinol Laryngol* 1985;94:542–6.
14. Srivastava AK, Das Gupta SM, Tripathi CB. A study of fatal strangulation cases in Varanasi (India). *Am J Forensic Med Pathol* 1987;8:220–4.
15. O'Halloran RL, Lundy JK. Age and ossification of the hyoid bone: Forensic implications. *J Forensic Sci* 1987;32:1655–9.
16. Porra S. Roentgenologic considerations of the hyoid apparatus. *Am J Roentgenol* 1969;105:63–73.

Additional information and reprint requests:
K. W. P. Miller
North Louisiana Criminalistics Laboratory
DNA Section
1115 Brooks Street
Shreveport, LA 71101